

A rare cause of tracheal obstruction: Ectopic thyroid

Published on 06.07.2014

DOI: 10.1594/EURORAD/CASE.11839

ISSN: 1563-4086

Section: Chest imaging

Area of Interest: Thorax Head and neck

Procedure: Diagnostic procedure

Procedure: Computer Applications-3D

Imaging Technique: Conventional radiography

Imaging Technique: Image manipulation / Reconstruction

Imaging Technique: CT

Special Focus: Congenital Chronic obstructive airways disease Case Type: Clinical Cases

Authors: Ammor H, Boujarnija H, Lamrani Y, Boubbou M, Maâroufi M, Kamaoui I, Tizniti S.

Patient: 23 years, female

Clinical History:

A 23-year-old female patient, operated for goitre in 2004, presented with complaints of difficulty in breathing, progressive breathlessness on exertion, cough and noisy breathing for the past 7 months. On clinical examination there were diffuse sibilant rhonchi.

Imaging Findings:

Chest radiography was normal (Fig. 1). Cervical and chest CT were performed and revealed a rounded soft tissue lesion in the posterior wall of the cervical trachea, significantly enhancing after injection of contrast medium (Fig. 2). The lesion protrudes to the tracheal lumen reducing its calibre considerably (Fig. 3), and exceeds the right tracheal wall coming in contact with the jugular and carotid vessels, and the prevertebral muscles.

Bronchoscopy depicted a smooth lesion in the trachea, protruding intraluminally just below the right vocal cord (Fig. 4, 5).

The patient was treated surgically with complete resection of the tumour and laryngotracheal anastomosis.

Pathological examination revealed that the mass corresponded to ectopic thyroid tissue.

Discussion:

Ectopic thyroid tissue is a rare developmental anomaly implicating abnormal embryogenesis of the thyroid gland during its passage from the floor of the primitive foregut to its final pre-tracheal position [1, 2].

It may be found in suprahyoid or infrahyoid location, along the thyroglossal duct and at the intralaryngotracheal area, with the latter being the rarest [3].

A clinical history of total thyroidectomy or goitre should be a reference point as to the aetiology of an intratracheal mass preoperatively [4].

Two theories may explain the origin of intratracheal thyroid tissue. First, a fetal anomaly could occur when the thyroid is splitted by the developing trachea and its cartilage rings. Second, thyroid tissue could rise into the tracheal lumen [5, 6].

Common clinical symptoms of Ectopic Intratracheal Thyroid (EITT) include progressive dyspnoea, stridor, cough,

difficulty swallowing, and haemoptysis [7].

Management of EITT is based on correct diagnosis. If a patient presents with upper airway obstruction, he/she should undergo complete exploration (flexible laryngotracheobronchoscopy, indirect laryngoscopy and imaging studies).

Computed tomography and magnetic resonance imaging are the examinations of choice for the diagnosis. They help identify the precise site, assess the degree of obstruction and explore the surrounding soft tissue and any other possible location of ectopic thyroid tissue. Malignancy is suspected if there is cervical lymphadenopathy or intratracheal invasion by the tumour [7].

Biopsy is required in order to confirm the diagnosis. Biopsy may cause severe bleeding as EITT is very vascular [8]. Correct management of EITT depends on the size of lesion, the patient's age, the existence of local signs, the status of thyroid function, and the histopathological findings [7].

Treatment options include surgical excision, thyroid-suppression therapy, and radioiodine ablation.

Surgical excision is indicated in cases with a large thyroid gland causing dyspnoea, or for cases of histologically proven malignancy [7].

Radioiodine ablation may cause radiation thyroiditis and/or tracheitis, exacerbating airway obstruction [7].

Furthermore, EITT may not take up iodine as effectively as the orthotopic thyroid gland, which may be destroyed by radioiodine ablation treatment [7] rendering radioiodine ablation potentially dangerous. It may be an alternative option for symptomatic elderly patients who refuse or are unsuitable for surgery.

Even though EITT remains uncommon, it should be considered as a possible cause of airway obstruction. A high degree of suspicion by physicians is essential in order to explore the possibility of EITT in patients presenting with airway obstruction symptoms, particularly in those who have a history of goitre.

Differential Diagnosis List: Ectopic intra-tracheal thyroid, Tracheal papilloma, Invasive thyroid carcinoma

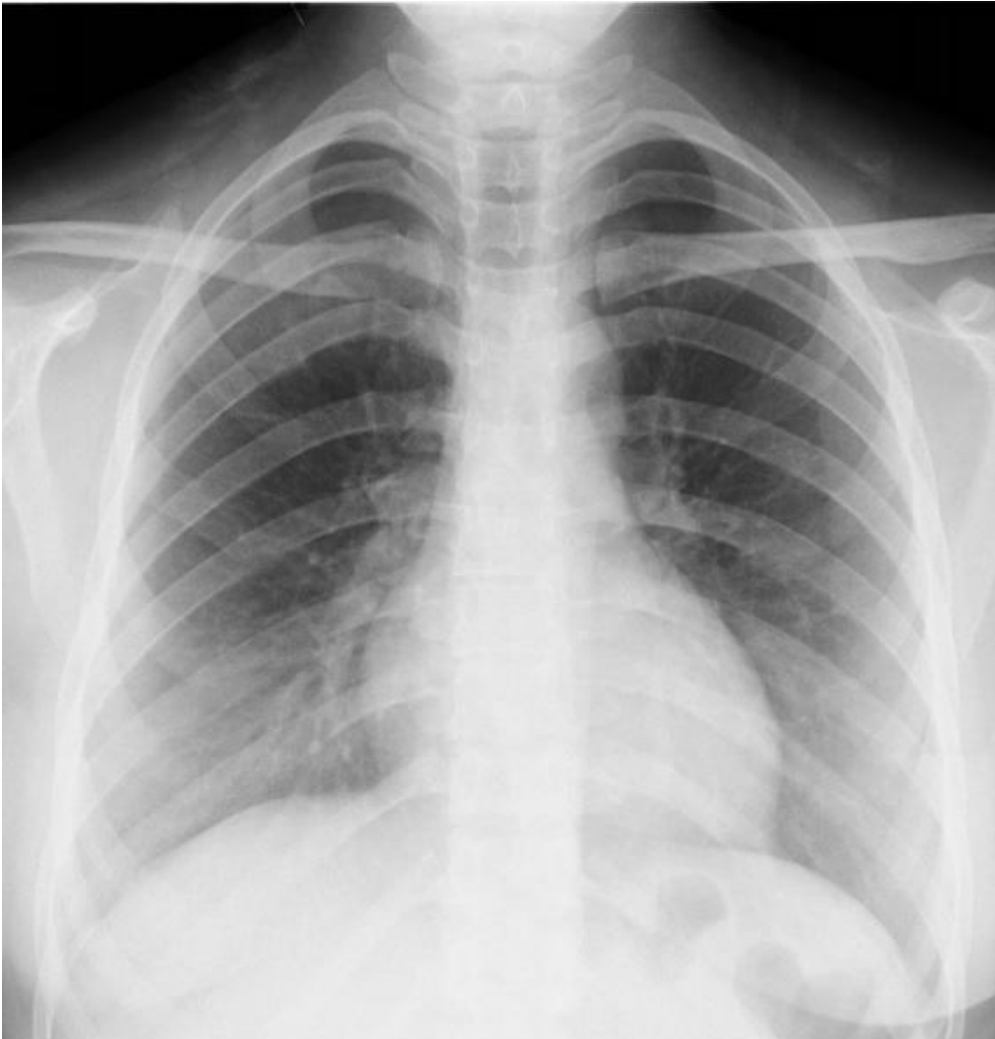Final Diagnosis: Ectopic intra-tracheal thyroid

References:

- Di Benedetto V (1997) Ectopic thyroid gland in the submandibular region simulating a thyroglossal duct cyst: a case report. *Journal of Pediatric Surgery* 32:1745–1746 (PMID: [9434015](#))
- Babazade F, Mortazavi H, Jalalian H & Shahvali E (2009) Thyroid tissue as a submandibular mass: a case report. *Journal of Oral Science* 51:655–657 (PMID: [20032623](#))
- K.K. Ramalingam, Ravi Ramalingam, Kanchan Dhote, Sreenivasa Murthy. T. M (2005) Ectopic Thyroid: A Rare Cause Of Tracheal Obstruction. *Indian Journal of Otolaryngology and Head and Neck Surgery* 57(3): 252-255 (PMID: [23120184](#))
- Bassam Abboud, Bassam Tabchy, Chawki Atallah, Rony Aouad, Nayla Matar, and Claude Ghorra (2007) Image In Endocrinology: Intratracheal Ectopic Thyroid Mass. *J Clin Endocrinol Metab* 92(1):26 –27 (PMID: [17047015](#))
- Muysoms F, Boedts M, Claeys D (1997) Intratracheal ectopic thyroid tissue mass. *Chest* 112:1684 –1685 (PMID: [9404773](#))
- Bowen-Wright HE, Jonklaas J (2005) Ectopic intratracheal thyroid: an illustrative case report and literature review. *Thyroid* 15:478 – 484 (PMID: [15929670](#))
- Yang et al (2010) Ectopic Intratracheal Thyroid. *Southern Medical Journal* 103(5):467-470 (PMID: [20375955](#))
- Dowling EA, Johnson IM, Collier FC, et al (1962) Intratracheal goiter: a clinicopathologic review. *Ann Surg* 156:258 –267 (PMID: [13887624](#))

Figure 1

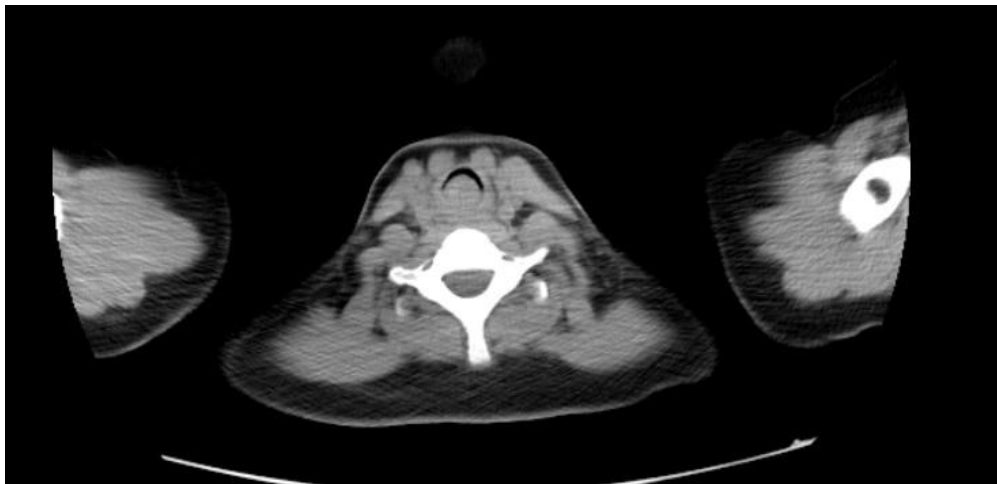
a



Description: There is no abnormality to explain the symptoms. **Origin:** Tizniti S, department of Radiology, CHU HassanII, FES, Morocco

Figure 2

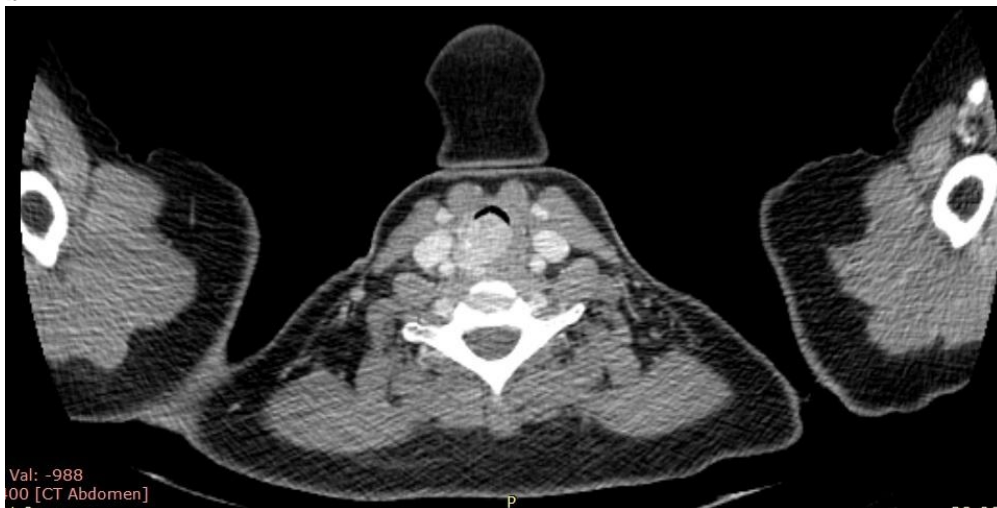
a



Description: Non-enhanced axial view: rounded soft tissue lesion in the wall of the trachea, protruding intraluminally and invading its wall, being in contact with cervical vessels and prevertebral muscles.

Origin: Tizniti S, department of Radiology, CHU HassanII, FES, Morocco

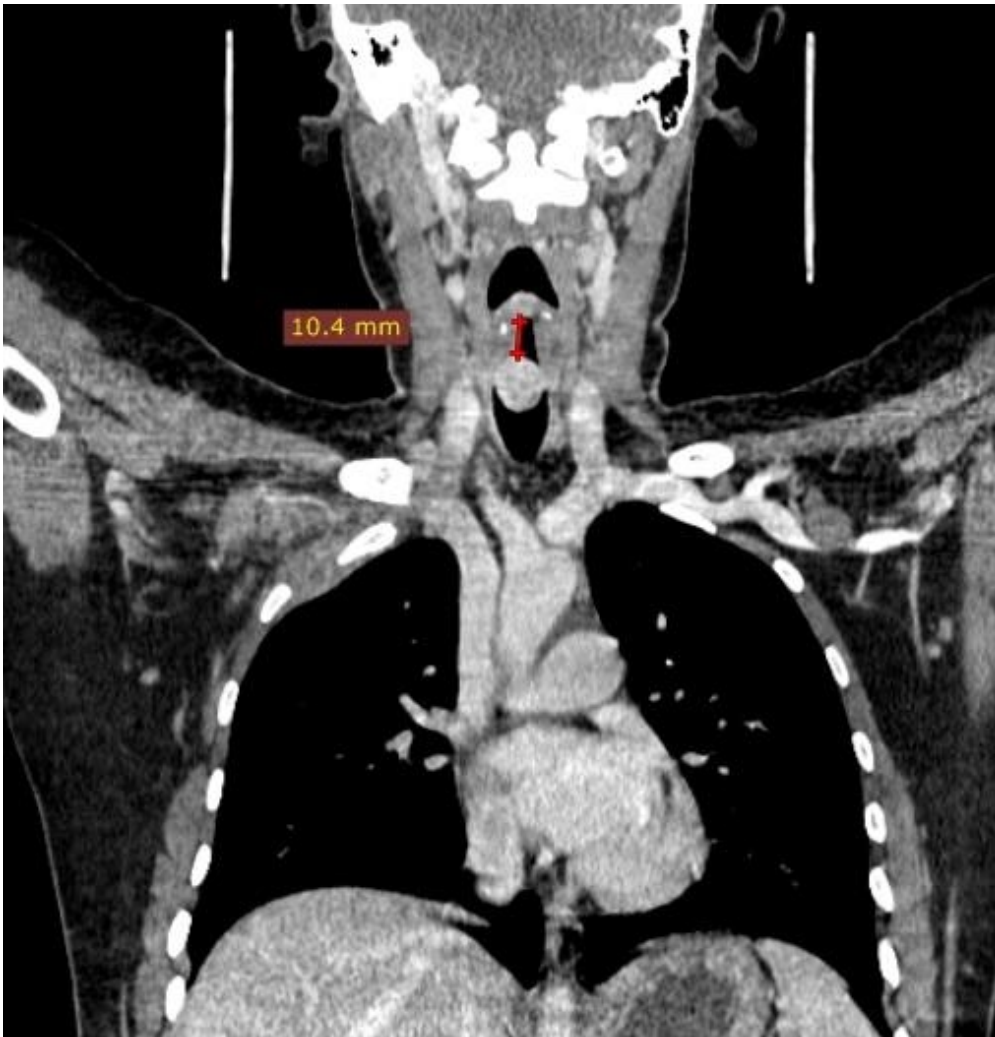
b



Description: Contrast-enhanced axial view: the lesion shows significant enhancement. **Origin:**

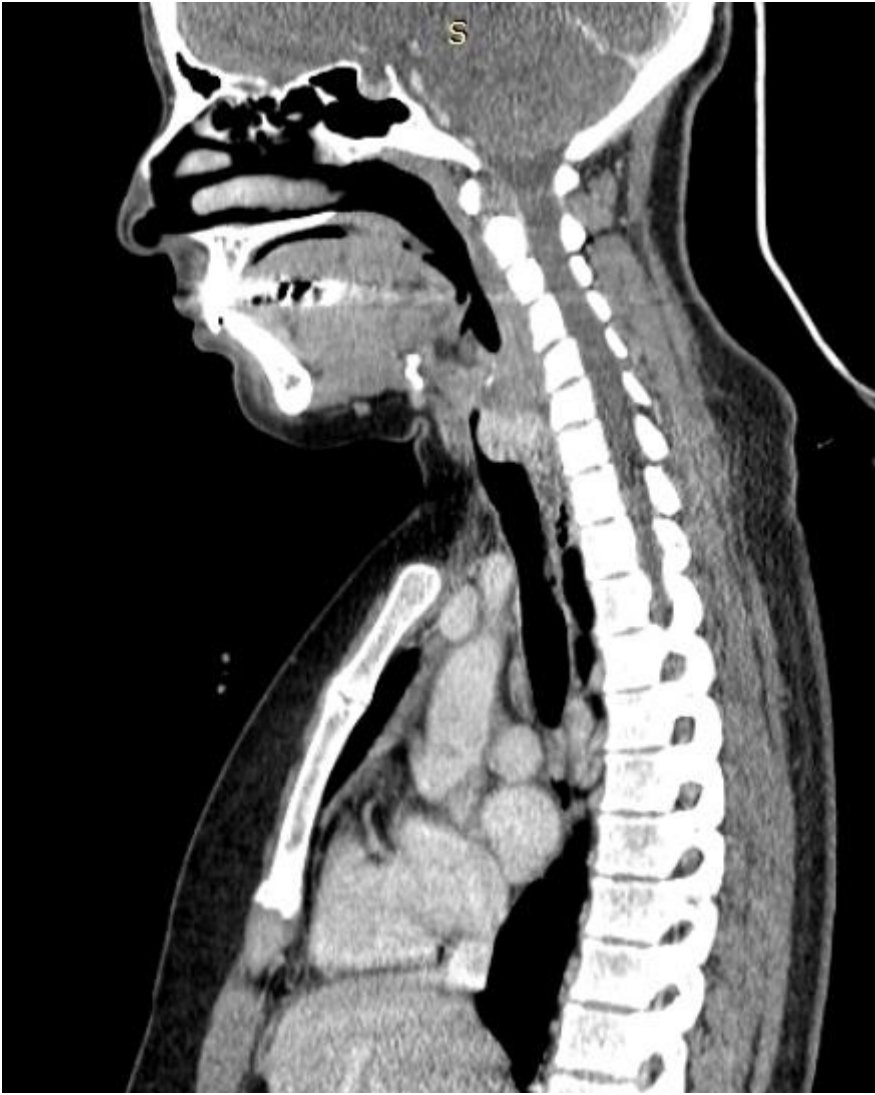Tizniti S, department of Radiology, CHU HassanII, FES, Morocco

c



Description: Contrast-enhanced coronal reformat: hyperenhancing rounded soft tissue lesion in the wall of the trachea, protruding intraluminally and invading its wall, being in contact with cervical vessels and prevertebral muscles. **Origin:** Tizniti S, department of Radiology, CHU HassanII, FES, Morocco

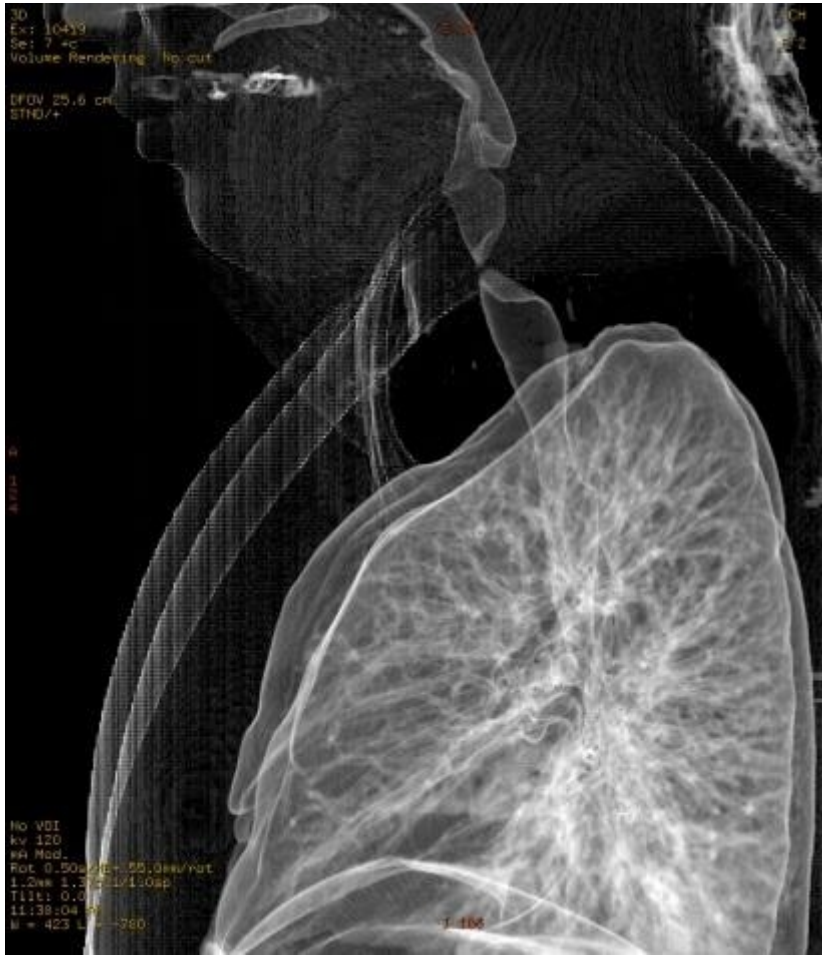d



Description: Contrast-enhanced sagittal reformat: hyperenhancing rounded soft tissue lesion in the wall of the trachea, protruding intraluminally and invading its wall, being in contact with cervical vessels and prevertebral muscles. **Origin:** Tizniti S, department of Radiology, CHU HassanII, FES, Morocco

Figure 3

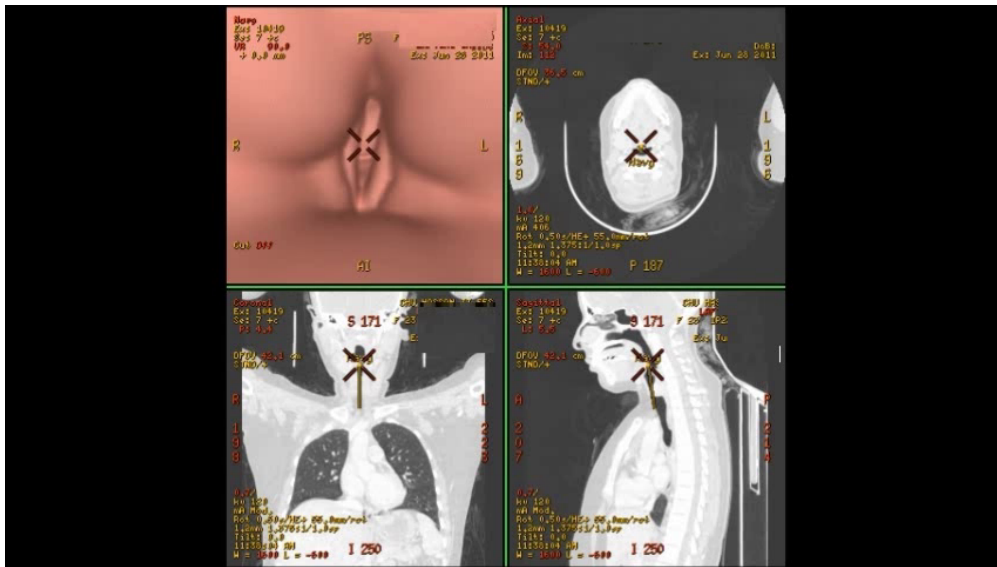a



Description: VR reconstruction of trachea and bronchial tree show an extreme narrowing of the cervical trachea. **Origin:** Tizniti S, department of Radiology, CHU HassanII, FES, Morocco

Figure 4

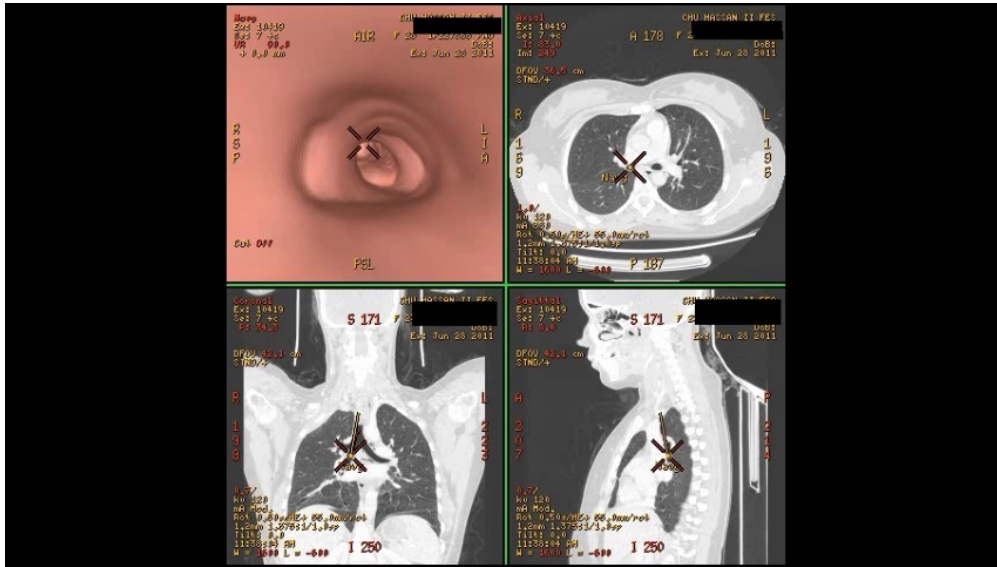
a



Description: CT virtual bronchoscopy - upper view: showing the location of the lesion just below the vocal cords level. **Origin:** Tizniti S, department of Radiology, CHU HassanII, FES, Morocco

Figure 5

a



Description: Inferior view of CT virtual bronchoscopy, showing better the obstruction of the tracheal lumen. **Origin:** Tizniti S, department of Radiology, CHU HassanII, FES, Morocco