

Primary leiomyosarcoma of inferior vena cava

Published on 30.08.2016

DOI: 10.1594/EURORAD/CASE.13880

ISSN: 1563-4086

Section: Uroradiology & genital male imaging

Area of Interest: Abdomen Veins / Vena cava Abdominal wall Vascular

Procedure: Diagnostic procedure

Imaging Technique: CT

Imaging Technique: Ultrasound

Special Focus: Neoplasia Case Type: Clinical Cases

Authors: Subbarao Chandana

Patient: 58 years, female

Clinical History:

Weight loss. Back pain. Prominent abdominal veins. Palpable mass in epigastrium.

Imaging Findings:

Ultrasound revealed an oval, lobulated hypoechoic mass expanding the inferior vena cava (IVC) with internal vascularity on colour Doppler. It measures 10cm x 5.5cm, involves the suprarenal and intrahepatic IVC and extends into the right renal vein. The hepatic veins are not involved.

Contrast-enhanced arterial phase CT demonstrated a large, lobulated, hypervascular retroperitoneal mass to the right of the abdominal aorta, inseparable from the IVC with extraluminal extension anteriorly. On delayed venous phase, the mass showed inhomogeneous enhancement with some areas of necrosis. No calcification or fatty elements are seen in the mass. Inferiorly it extends into the right renal vein. No mass is seen in the right kidney.

A non-enhancing filling defect suggestive of a thrombus is also seen in the distal IVC. Dilated collateral veins are seen on anterior abdominal wall and around the liver, bypassing the obstructed segment of IVC. No evidence of intra-abdominal lymphadenopathy or other retroperitoneal mass.

Discussion:

Malignant involvement of IVC is rare and may be due to primary leiomyosarcoma or tumour thrombus. Tumour thrombus is more common.

Primary leiomyosarcoma of IVC arises from smooth muscle in the media of IVC. It is the commonest primary tumour of IVC with strong predilection for 40-60 year old women [1] (male to female ratio of 1:5).

Clinical features and resectability depend on the segment of IVC involved - lower segment below renal veins, middle segment between renal and hepatic veins or upper segment above hepatic veins. Leiomyosarcoma of IVC most commonly involves the middle third. The tumour starts in the wall and as it grows, it can be predominantly intraluminal (33%) or predominantly extraluminal (66%) [2]. Extraluminal tumours may invade adjacent structures. Haematogenous metastasis to liver, lungs and brain is common. Lymphatic spread to local nodes may occur in late stages [3].

Clinical presentation is non-specific with weight loss, malaise, abdominal and back pain. Infrarenal leiomyosarcomas

are often slow growing, develop adequate collateral circulation and cause venous obstruction only late in the disease. Tumours of middle segment may involve the renal veins and present with nephrotic syndrome. Tumours of upper segment may involve the hepatic veins and present with varying degrees of Budd-Chiari syndrome [4].

Accurate identification of superior extent of tumour is vital for surgical planning and management. Ultrasound, CT and MRI demonstrate a lobulated enhancing mass expanding or encasing the IVC with or without involvement of renal / hepatic veins. Ultrasound can often accurately localize it to the IVC. CT in arterial and delayed venous phase is important to demonstrate hypervascularity and extent of tumour. Histological diagnosis is possible with ultrasound or CT-guided biopsy.

Extraluminal IVC leiomyosarcoma should be differentiated from other retroperitoneal tumours and this can sometimes be difficult [5]. Tumour thrombus can be differentiated from bland thrombus by venous expansion, enhancement in the 'mass' and direct continuity between thrombus and tumour in another organ (liver / kidney).

Complete surgical resection with microscopically clear margins is required for cure. Complete resection is possible when lower segment is involved. Tumours involving middle segment need more complicated en bloc resection of IVC, involved renal vein and kidney followed by IVC graft. Upper segment tumours involving right atrium or hepatic veins have the worst prognosis as complete resection is often impossible [6].

Prognosis is poor. Overall 10 year survival is 14% and more than 50% of patients develop recurrent disease.

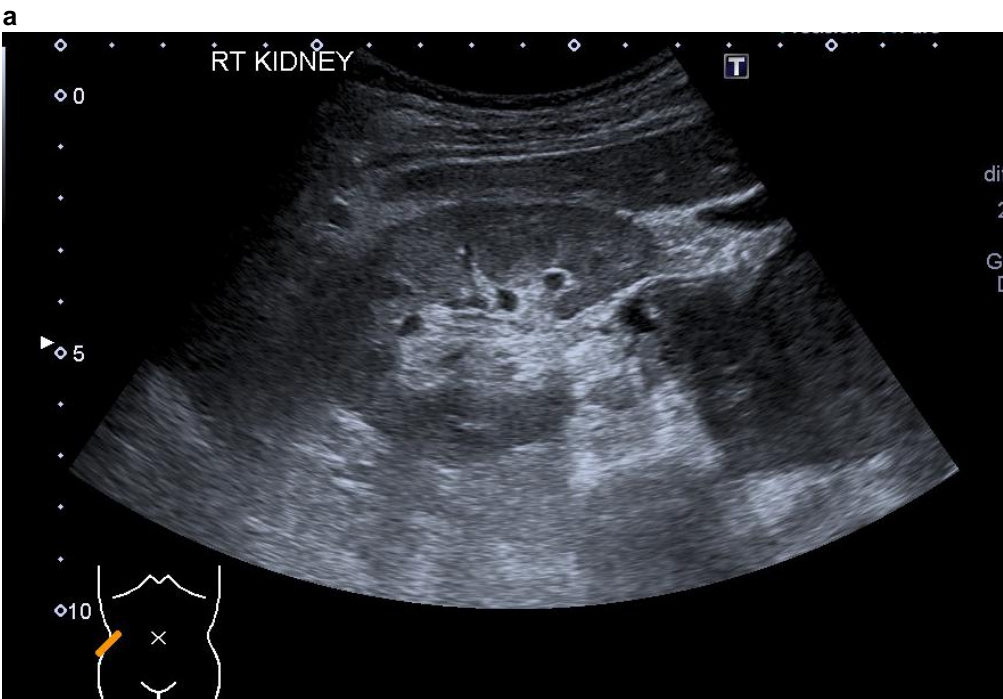
Differential Diagnosis List: Primary leiomyosarcoma of inferior vena cava, Retroperitoneal sarcoma, Tumour thrombus in right renal vein extending into IVC, Bland thrombus in IVC

Final Diagnosis: Primary leiomyosarcoma of inferior vena cava

References:

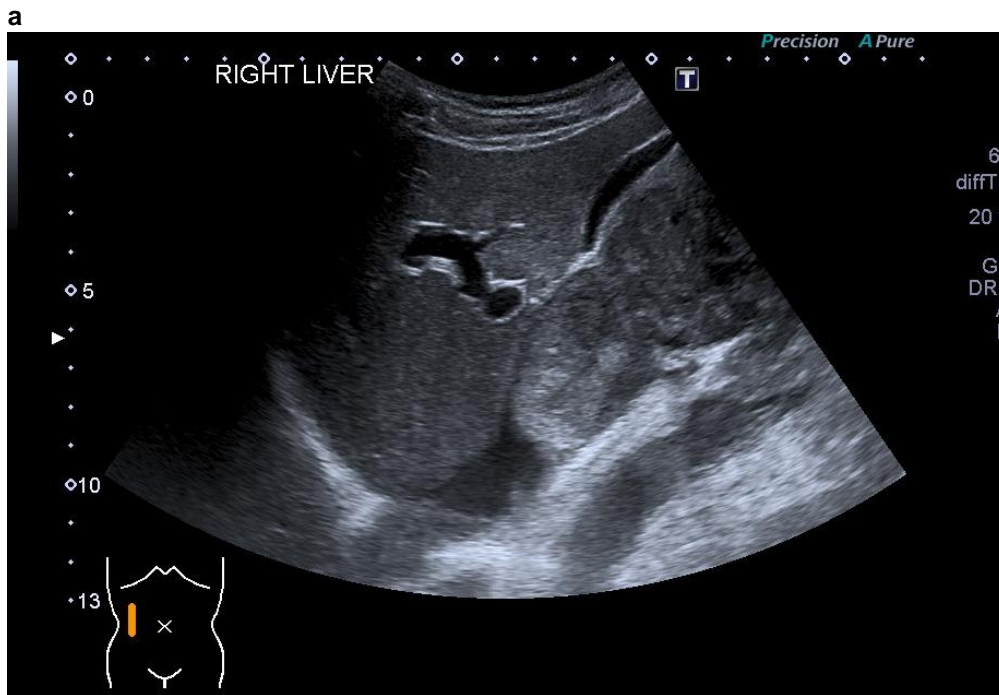
- Smillie RP, Shetty M, Boyer AC, Madrazo B, Jafri SZ (2015) Imaging evaluation of the inferior vena cava. *Radiographics* 35(2):578–592 (PMID: [25763740](#))
- Hartman DS, Hayes WS, Choyke PL, Tibbetts GP (1992) From the archives of the AFIP. Leiomyosarcoma of the retroperitoneum and inferior vena cava: radiologic-pathologic correlation. *Radiographics* 12(6):1203-20 (PMID: [1439022](#))
- Ahluwalia A, Saggar K, Sandhu P, Gupta K (2002) Primary leiomyosarcoma of inferior vena cava : an unusual entity. *Indian Journal of Radiology and Imaging* 12(4):515-516
- Gay SB, Sistrom CL, Pevarski DJ, Feldman PS (1993) Inferior vena cava mass and Budd-Chiari syndrome. *Invest Radiol* 28(8):774-6 (PMID: [8376012](#))
- Sessa B, Iannicelli E, Caterino S, D'Angelo F, Milione M, Ziparo V, David V (2010) Imaging of leiomyosarcoma of the inferior vena cava: comparison of 2 cases and review of the literature. *Cancer Imaging* 10(1): 80–84 (PMID: [20233678](#))
- Mönig SP, Gawenda M, Erasmi H, Zieren J, Pichlmaier H (1995) Diagnosis, treatment and prognosis of the leiomyosarcoma of the inferior vena cava. Three cases and summary of published reports. *Eur J Surg* 161(4):231-5 (PMID: [7612763](#))

Figure 1



Description: Origin:

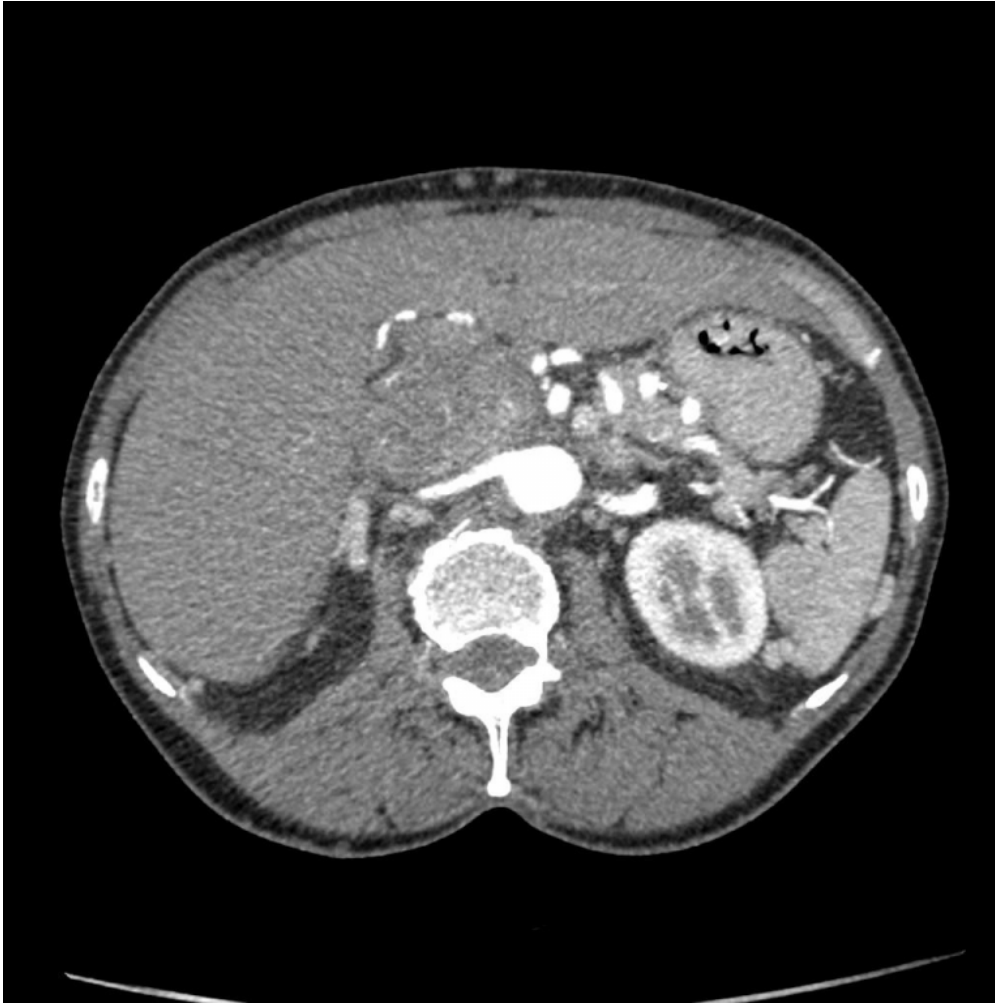
Figure 2



Description: Lobulated mass within the suprarenal and intrahepatic segments of IVC, distending the vein. The mass stops short of the hepatic veins. **Origin:** Department of Imaging, Leighton Hospital, Mid Cheshire Hospitals NHS Foundation Trust, UK

Figure 3

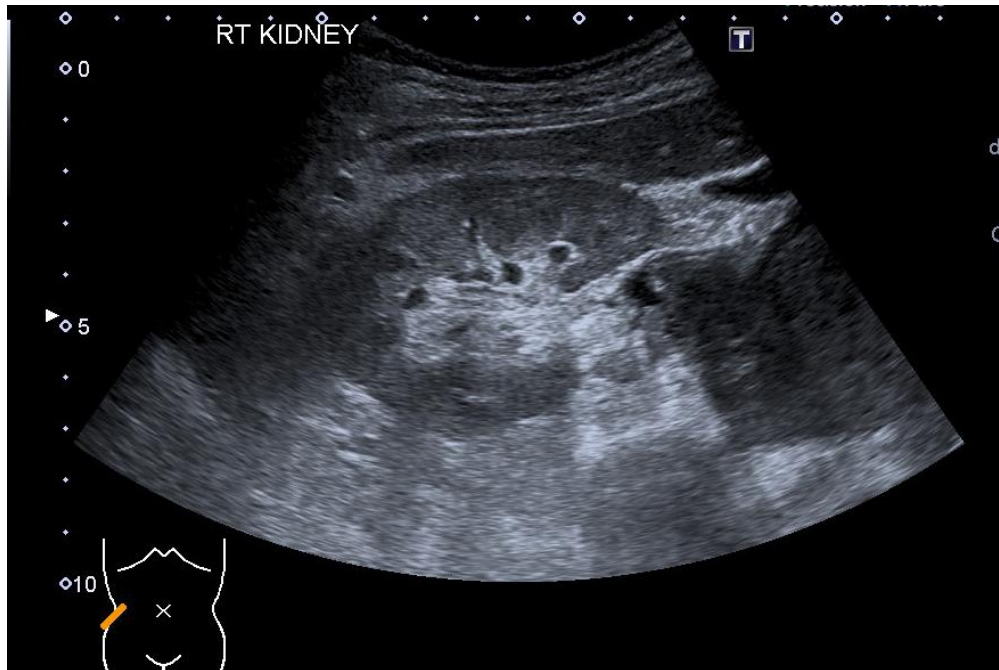
a



Description: Hypervascular mass anterior and to the right of abdominal aorta. The lesion is inseparable from the IVC. Note the dilated subcutaneous veins in anterior abdominal wall. **Origin:** Department of Imaging, Leighton Hospital, Mid Cheshire Hospitals NHS Foundation Trust, UK

Figure 4

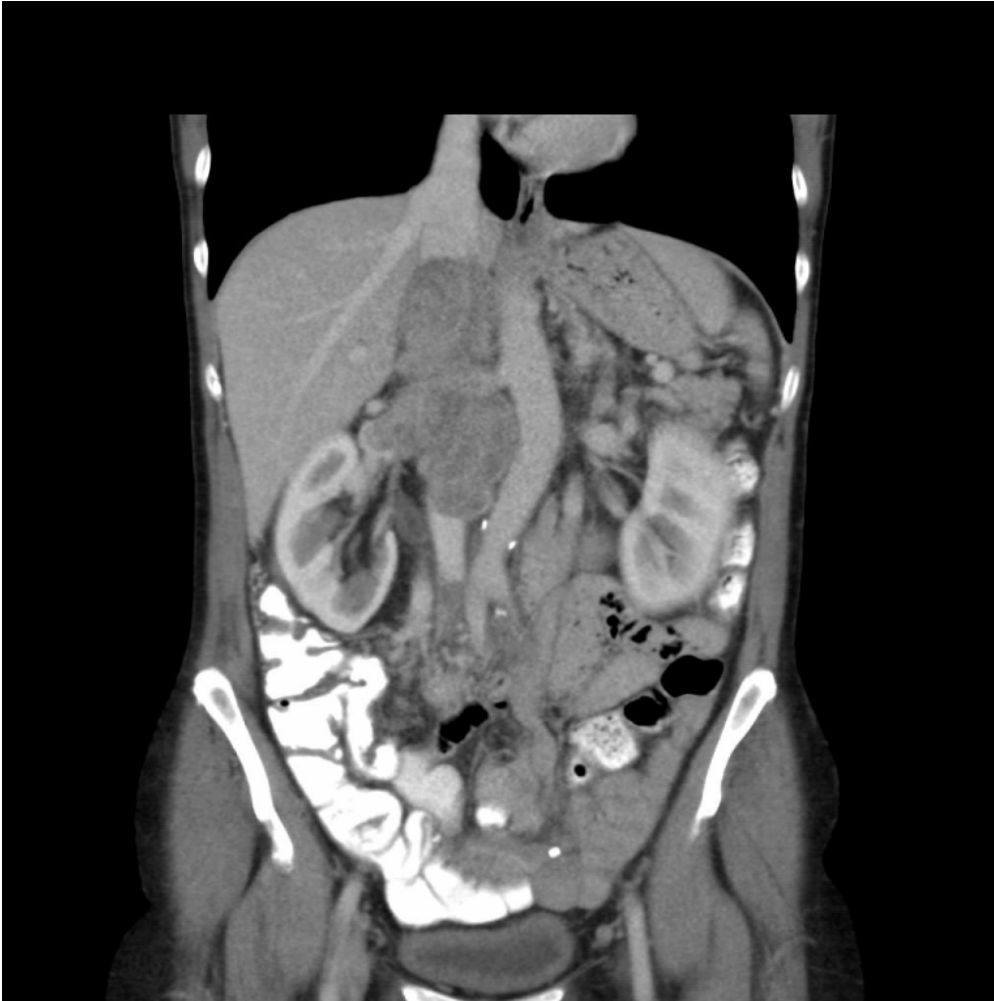a



Description: Hypoechoic mass seen medial to right renal hilum involving renal vein and IVC. **Origin:** Department of Imaging, Leighton Hospital, Mid Cheshire Hospitals NHS Foundation Trust, UK

Figure 5

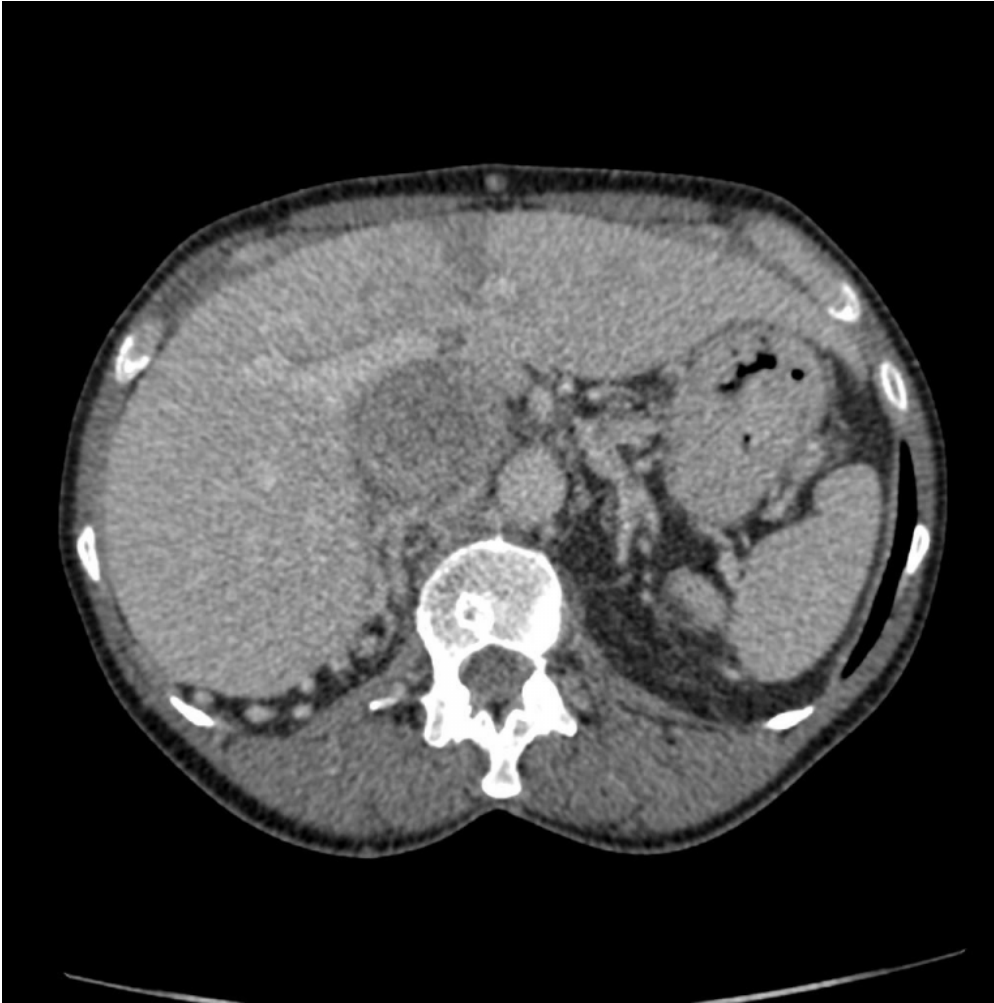a



Description: Large lobulated heterogeneously enhancing mass involving lower and mid segments of IVC extending into right renal vein. The mass stops short of the hepatic veins. Thrombus is also seen in distal IVC. **Origin:** Department of Imaging, Leighton Hospital, Mid Cheshire Hospitals NHS Foundation Trust, UK

Figure 6

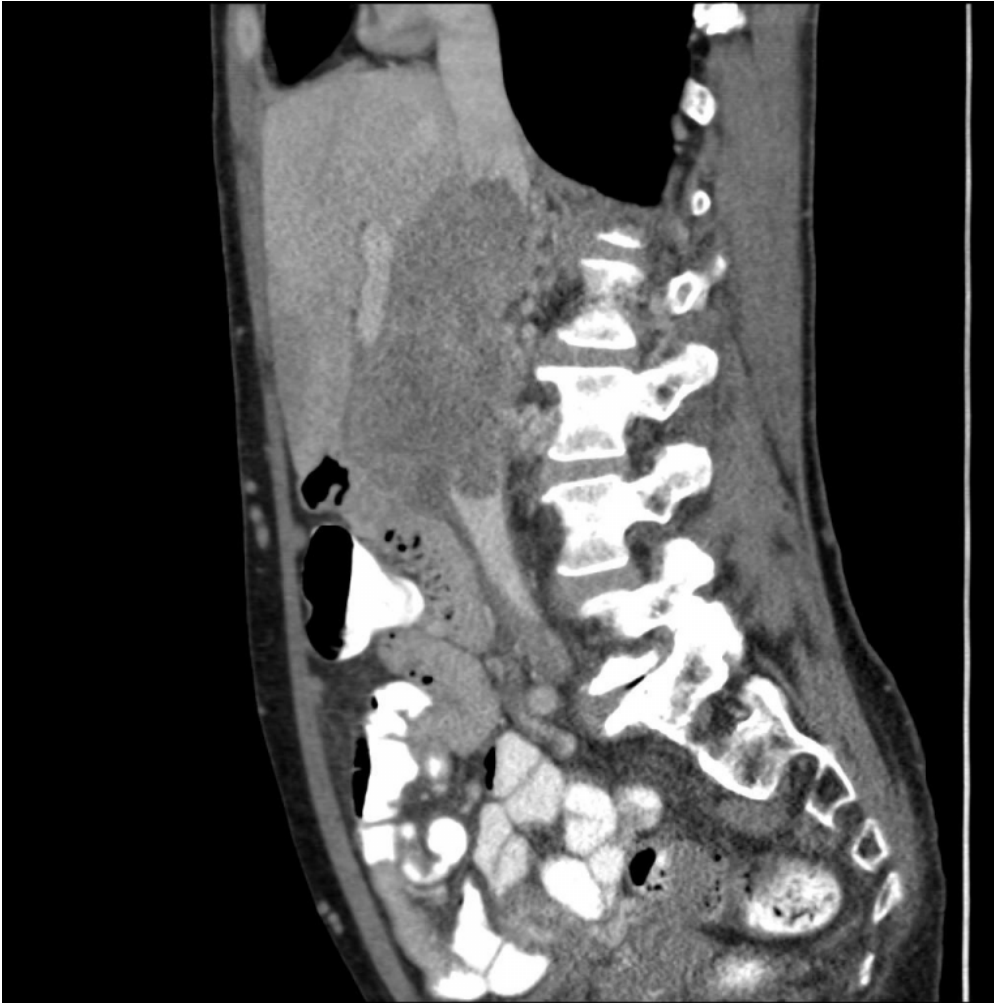a



Description: Heterogeneously enhancing retroperitoneal mass which is in the location of IVC. Note the dilated collateral veins posterior to liver. **Origin:** Department of Imaging, Leighton Hospital, Mid Cheshire Hospitals NHS Foundation Trust, UK

Figure 7

a



Description: Lobulated, enhancing mass in the IVC with extraluminal component anteriorly. A bland thrombus is also seen in distal IVC. **Origin:** Department of Imaging, Leighton Hospital, Mid Cheshire Hospitals NHS Foundation Trust, UK